

PennHIP Report

Referring Veterinarian: Dr Zoran Djordjevich	Clinic Name: Mohnacky Animal Hospital of Carlsbad
Email: carlsbad@mohnackyyvet.com	Clinic Address: 2505 S. Vista Way Carlsbad, CA 92008
	Phone: (760) 729-3330
	Fax: (760) 729-2536

Patient Information

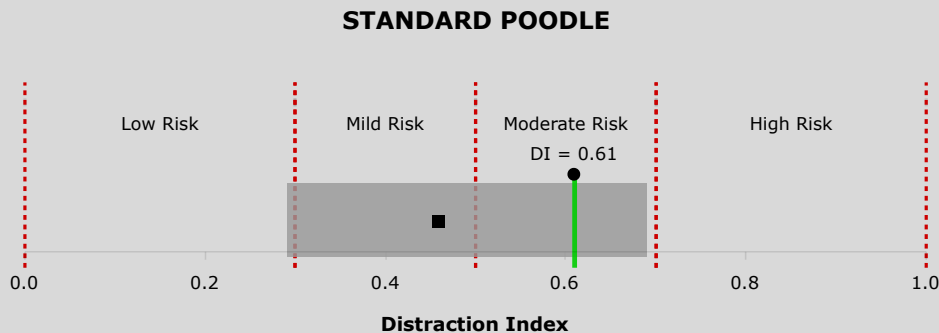
Client: De Lisle, Ashley	Tattoo Num:
Patient Name: Lark	Patient ID: C156715
Reg. Name: Apricot P&G's meadowlark	Registration Num:
PennHIP Num: 172350	Microchip Num: [REDACTED]
Species: Canine	Breed: STANDARD POODLE
Date of Birth: 18 Nov 2021	Age: 5 months
Sex: Female	Weight: 23.6 lbs/10.7 kgs
Date of Study: 19 Apr 2022	Date Submitted: 19 Apr 2022
Date of Report: 21 Apr 2022	

Findings

Distraction Index (DI): Right DI = 0.61, Left DI = 0.50.
 Osteoarthritis (OA): **No radiographic evidence of OA for either hip.**
 Cavitation/Other Findings: No cavitation present.

Interpretation

Distraction Index (DI): The laxity ranking is based on the hip with the greater laxity (larger DI). In this case the DI used is 0.61.
 OA Risk Category: The DI is between 0.50 and 0.69. This patient is at moderate risk for hip OA.
 Distraction Index Chart:



BREED STATISTICS: This interpretation is based on a cross-section of 5308 canine patients of the STANDARD POODLE breed in the AIS PennHIP database. The gray strip represents the central 90% range of DIs (0.29 - 0.69) for the breed. The breed average DI is 0.46 (solid square). The patient DI is the solid circle (0.61).

SUMMARY: The degree of laxity (DI = 0.61) falls within the central 90% range of DIs for the breed. This amount of hip laxity places the hip at a moderate risk to develop hip OA. **No radiographic evidence of OA for either hip.**