

PennHIP Report

Referring Veterinarian: Dr Zoran Djordjevich	Clinic Name: Mohnacky Animal Hospital of Carlsbad
Email: carlsbad@mohnackyvet.com	Clinic Address: 2505 S. Vista Way Carlsbad, CA 92008
	Phone: (760) 729-3330
	Fax: (760) 729-2536

Patient Information

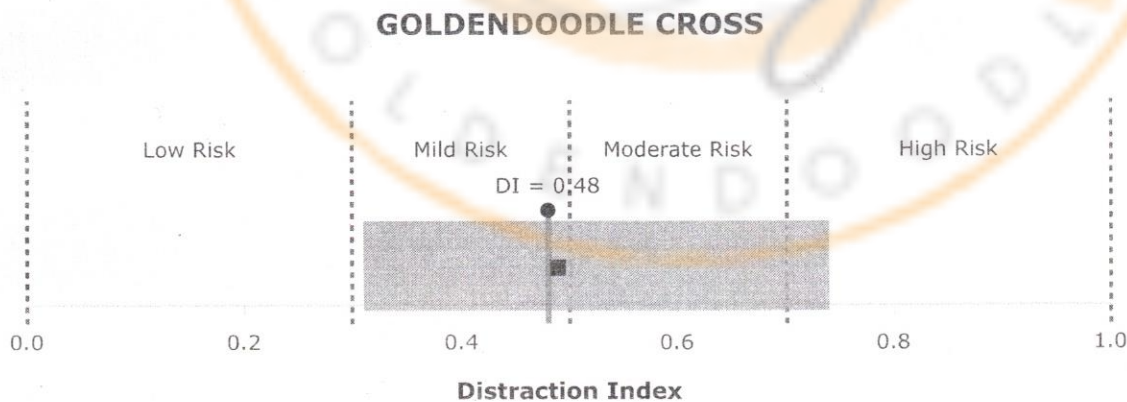
Client: de lisle, ashley	Tattoo Num:
Patient Name: fiona	Patient ID: c157539
Reg. Name:	Registration Num:
PennHIP Num: 176056	Microchip Num:
Species: Canine	Breed: GOLDDOODLE CROSS
Date of Birth: 28 Jan 2022	Age: 6 months
Sex: Female	Weight: 46.6 lbs/21.1 kgs
Date of Study: 06 Jul 2022	Date Submitted: 07 Jul 2022
Date of Report: 07 Jul 2022	

Findings

Distraction Index (DI): Right DI = 0.48, Left DI = 0.41.
 Osteoarthritis (OA): No radiographic evidence of OA for either hip.
 Cavitation/Other Findings: No cavitation present.

Interpretation

Distraction Index (DI): The laxity ranking is based on the hip with the greater laxity (larger DI). In this case the DI used is 0.48.
 OA Risk Category: The DI is between 0.31 and 0.49. This patient is at mild risk for hip OA.
 Distraction Index Chart:



BREED STATISTICS: This interpretation is based on a cross-section of 2775 canine patients of the GOLDENDOODLE CROSS breed in the AIS PennHIP database. The gray strip represents the central 90% range of DIs (0.31 - 0.74) for the breed. The breed average DI is 0.49 (solid square). The patient DI is the solid circle (0.48).